

THE CAUCASIONI COMPONENT OF INDIVIDUALS FROM HOVHANNAVANK MONUMENT

Nyura Hakobyan
Aghavni Zhamkochyan
Anahit Khudaverdyan

Institute of Archaeology and Ethnography, NAS RA

Abstract

The population of medieval Armenia was not homogeneous. Some combinations of craniological features of South-European race are extant. According to the craniological data on our disposal today, among the late medieval population of Hovhannavank are present specific complexes of features not characteristic for the Armenian population of later periods. This complex of features stands close to the Caucasioni type. Closest analogues to that type were found among the populations of Georgia, Azerbaijan (Mingechaur) and Iran (Turang Tepe). Based on anthropological and palaeopathological data, two types of deformation were observed: circular high (high ring) and low. Pathological changes represent a certain adaptation form to ecobiological and social environmental factors. Leading among the unfavorable environmental factors is considered the general infectious background.

Keywords: *Armenia, Hovhannavank, anthropology, Caucasioni type, deformation of the head, palaeopathology*

Hovhannavank is one of the medieval monastic complexes of Armenia which is located at the edge of a rocky cliff of the Kasakh River, opposite Mount Araler (2600 m.), Aragatsotn district (Pic. 1). From three sides Hovhannavank is defended by long mighty walls, and from the fourth side – by natural barrier, the slopes of a mountain which towers above the river.¹ Moritz Wagner who visited the monastery in the XIX century, wrote: “When you look on the deep gorge from the slopes of Aragats it unveils an extremely picturesque and magnificent panorama. Through the gorge flows the River Aparan (Khasakh). This breathtaking sight you can enjoy from the territory of St. Hovhannavank”.² Hovhannavank monastery is the masterpiece of the XIII century Armenian architecture due to its magnificence, narthex, elegant sculptures and rational architectural solutions.³ Hovhannavank was not only a complex of churches but also a well known convent: “Thus under the patronage of St. Karapet among numerous brothers-hermits was written and given to this holy brotherhood this delighting [the soul]

¹ Ghafadaryan 1948: 42.

² Shahaziz 1987: 303.

³ Toramanyan 1948: 55.

history as commemoration of his soul”⁴. In 1243 Kurd Vachutyan moved the diocesan episcopal throne of Aragatsohn from the fortress of Amberd to Hovhannavank.⁵

Hovhannavank consists of two churches – one-naved arched basilica and a church with a spacious narthex-chapel on the western side. According to the tradition, due to the assistance of king Trdat Gregory the Illuminator had founded a basilic church early in the IV century AD, posted there holy relics of John the Baptist and consecrated the building. The basilics dedicated to John the Baptist was named after St. Karapet. In spite of numerous reconstructions, the one-naved basilica, without doubt, belongs to the first phase of the development of Christian architecture, to the IV or V centuries, and keeps planning solutions which speaks in favor of earlier dating: “The most ancient basilica of Hovhannavank by its planning proportions, - mentions T.Toramanyan – was built in the early V century at latest, and the problem of more early dating should be find out step by step”.⁶

On the restoration and changes of the monastery of Hovhannavank wrote also Garegin Hovsepyan: “The modern building of Hovhannavank belongs to the XIII century. On its northern side, though, is located one-naved church, some features of which point on the idea that it is a building founded before the VII century. The church was restored many times, but it had kept ancient elements such as semi-columns on both sides of the entrance and remains of horseshoe-like arch from inside which are characteristic for our ancient and basilic churches. Hovhannavank is mentioned in the texts of 603-606 AD and modern sources as well. Also the tradition which has ancient roots says that it was built by Gregory the Illuminator at the beginning of the IV century”.⁷ The next and fundamental reconstruction of the basilica took place in the mid-XVII century (in 1652) by the abbot Zakariya Vagharshapattsi.⁸ But the church of St Karapet was not meant to be unharmed. During the destructive earthquake of 1679 it was ruined once more: “.... In the Holy mansion of Hovhannavank had collapsed all beautiful dwellings, the church had fallen and we escaped the death”, - with great sorrow wrote the Deacon Zakariya (Kanakertsi).⁹

The architectural planning of the St Karapet church is simple, without elements of ornamentation, except the frescos of the second half of the XIX century.

⁴ Kanakertsi 1870: 5-6.

⁵ Manucharyan 2019: 98.4.

⁶ Toramanyan 1948: 131.

⁷ Hovsepyan 1944: 20.

⁸ Davrizhetsi 1891: 268.

⁹ Kanakertsi 1870: 104.



Fig. 1. The location of the monastic complex of Hovhannavank

In Hovhannavank, on the tympanum of the western portal of cathedral is located a bas-relief depicting parables about sane and insane maidens. The occurrence of this parable on the church tympanum is not characteristic for the Armenian art, although the tradition of decoration of tympanums in the XIII-XIV centuries was widely practiced in Armenia, but its sculptural representation among Armenian monuments exists only in Hovhannavank.¹⁰ In the center is depicted a figure of Christ sitting on the throne. His right arm is stretched over the heads of sane virgins, pointing on their righteous deeds. The pictures of five sane virgins are placed one after another, with raised hands holding candles, while the insanes stand with fatigued heads, as if they are rejected.

The erection of the Catholic church was initiated in 1216 according to the inscription on the western wall of the north-eastern sacristy. "By the will of beneficent Lord, during the rule of the son of Zakare, great Shahnshah and the rule of the son of Vache, *kusaka*¹¹ amir Kurd in our province (Aragatsotn), in 1221 I, vardapet Astvatsatur, with the assistance of the members of monastic brothers, and as a spiritual son of Vardapet Akopos, had initiated the erection of a wonderfully decorated Catholic church". It means that the erection of the Catholic church lasted six years, from 1216 until 1221. The church survived until 1918, when it had suffered during the earthquake. It was completely restored in 1990s.

Church-narthex. This building is characteristic for the architecture of the XIII century. In the central part is located a big hall and a dome which stands on four columns, and in the center of the dome is a rounded hole. On the dome stands bell-tower which has 12 columns. Four columns of the church are connected with the walls by means of high-spanning arcs which rise above the pylons. It is generally accepted that the narthex was built by the prince Kurd, son of Vache. The erection had begun in 699 (1247 or 1248) of Armenian chronology and concluded in 700, i.e. 1251.¹² The

¹⁰ Zakaryan 1973: 294.

¹¹ Kusakal – governor of the region or country in the medieval Armenia.

¹² Ghafadaryan 1948: 39.

narthex is remarkable for exclusively rich inner decoration - *khachkars* (cross-stone) decorated with relief ornaments, frescos, openwork floral and geometric ornamentation. Narthex served as a tomb where were buried representatives of highest priesthood and abbots, priests and members of their families. "Priest Kurd himself, - as wrote Zakaria Kanakertsi, - leaving earthly glory, went to the island of Sevan, clothed like hermit, became a clergyman, had died there and buried in the narthex of the church".¹³

Walls of the fortress. The inscription mentioning the building of the fortress wall was found to the north of the monastic complex, on the podium of a *khachkar* placed in the cemetery. *Khachkar* itself was lost but we possess with information kept in the study of Zakaria Kanakertsi. According to him, the inscription tells that the wall of the fortress was built by the dearly departed Nana, spouse of the king Abgar Kyurikyan, or, thanks to the financial aid of Vaneni (as it is mentioned on the inscription carved on the Sanahin bridge).¹⁴ K.Ghafadaryan thinks that the erection of the wall and the bridge had initiated Nana after the death of her husband (in 1192), hence, in 1190s or at the beginning of the XIII century.¹⁵

The wall was built of the solid local stone of cubic form. The southern and northern parts of the wall are preserved better than others. One of the colophons writes: "Inside old fortress walls, from the southern part of the church were built household facility, refectory and cells".¹⁶

The cleaning and excavations were undertaken in July-August, 2015, near the northern wall (from outside) of the basilic church. The territory was covered by soil and construction waste. In the course of cleaning, in approximately 1 meter deep were opened mills for vine and skeletal remains of 9 individuals. Previously, during the cleaning immediately under the wall were unearthed some *karases* for wine.

The mill for vine. "A trough for vine. A pit or reservoir where vine is milled. Are distinguished mills for vine and oil. Mills for vine were called small mills which were troughs made of clay, sometimes in the shape of a boat", - is written in the Haykazyan vocabulary.¹⁷ It means that the cultivation of vine and wine-making has very old tradition so that in the Armenian language were formed such concepts-phrases. "I will now show what seems to me the most marvelous thing in the country, - writes Herodotus, the father of history, - Their boats which ply on the river and go to Babylon (Assyrians) are all of skins, and round. They make these in Armenia, higher up the stream than Assyria. First they cut frames of willow, then they stretch hides over these for a covering ... Then they fill it with reeds and send it floating down the river with a cargo; and it is for the most part palm wood casks of wine that they carry down. So when they have floated down to Babylon and disposed of their cargo, they sell the framework of the boat and all

¹³ Kanakertsi 1969: 218.

¹⁴ Orbeli 1915: v. IV, p. II.

¹⁵ Ghafadaryan 1948: 43.

¹⁶ Alishan 1890: 173.

¹⁷ New Dictionary 1981: 108.

the reeds; the hides are set on the backs of asses, which are then driven back to Armenia".¹⁸

The existence of vine mills on the territory of the monastery is proved through the inscription carved on the southern wall of the narthex of the Catholic church: "In 1279 or 1280, the servants of Christ – Vardan Vardapet and Mkhitarich, have done a great job ... they gave to the church Konteghut which was the birthplace of St Karapet monastery, built expensive mills of vine".¹⁹ Next to the northern wall of basilica (from outside) were opened four pits of the mill built of big rough stones, plastered with whitewash (width of the layer – 2 cm.). The pits are cylindrical, deep, with small diameter of their edges, 1.9–2.5 m deep, diameter of holes - 35–45–56 cm. On the bottom of the second pit (numbering is conditional) is preserved a deepening (15×15 cm) where the grape must was collected. The hole of the pit was closed through a rough stone. Similar vine mills were opened in Aruch, Ashnak, Garni, on the territory of the Echmiatsin Cathedral church (on the northern part) and other places. They are dated with the XI–XIV centuries. We consider that the Hovhannavank vine mills also had similar construction, built towards the end of the XIII century. Next to the pits were opened burials of some individuals.

The monastery possesses with guesthouse, residence of the chief of the eparchy, library, school and other outbuildings which now are destroyed. The preserved ruins presumably belong to the period of Zakaria Kanakertsi. The deacon Zakaria Kanakertsi and Yervand Shahaziz testify that at the monastery functioned a school where high-ranked rabbis and teachers work.

Excavations revealed, besides the whole planning of the monastery also a limited number of informative repertoires of glazed and unglazed pottery. The collection was completed with fragments of kitchen vessels made of faience. These pieces of ceramics were imported from the neighboring Iran. Probably, this ceramics was intended for the service of the guests who relax in the peaceful abode with great pleasure. As to the hermits and pupils of the school, they live quiet and modestly.

Skeletal materials unearthed during the excavations of 2015 had been studied according to the well known anthropological methodology.²⁰ All skulls were visually examined in order to determine the existence of damages during the lifetime, traces of illness and some genetically inherited symptoms.²¹

Individual N. 1. The remains belong to a woman, whose biological age could be determined approximately between 45–55 years. It is characterized as common gracile body type, with very poorly expressed relief of the brow. The individual has an artificial frontal-occipital deformation and asymmetry of the skull (plagiocephalia)(Fig. 2).

¹⁸ Herodotus 1986, 1.194, 79–80.

¹⁹ Kostanyants 1913: 121, inscription N. 406. 1; Ghafadaryan 1948: 73, inscription N. 57.

²⁰ Alekseev, Debets 1964: 52; Zubov 1968a: 10; 1968b: 139; Buikstra, Ubelaker 1994: 17; Ubelaker 1989.

²¹ Movsesyan, Mamono, Richkov 1975: 129; Goodman et al. 1984: 13–49, Goodman, Armelagos 1989: 225–243; Aufderheide, Rodriguez-Martin 1998; Ortner, Putschar 1981; Ortner 2003.




Fig. 2. Individual N. 1.

Individual craniological data is represented in the Table 1. In the vertical norm the skull form corresponds to the sphenoid variant. Brain box is characterized as a brachycranial with middle longitudinal very big transversal high-rise diameter. The height of the skull is characterized by hypsicrania and tapaneocrania. The relief of the lower edge of the frontal bone scale is poorly developed (score 1). The greatest width of the forehead is very big, the smallest one is of medium size. The face is orthognathic, low and medium wide, orbits medium high and medium wide, the height of the nose very big, width – big. The lowest edge of the pear-shaped hole has sharp form. Anterior nasal spine is estimated by the score 4. The length of the lower jaw is medium, the smallest width of the bough is small, and height is big. The symphysis is not high, the height of the body very small, and the width is medium.

On the skull are seen the next discrete-varying features: *foramina supraorbitalia*, *foramina frontalia*, *foramina zygomaticofacialies*, *foramina mastoidea*, *foramina mentalia*, *os zygomaticum bipartitum*, *spina processus frontalis ossis zugomatici*, *stenocrotaphia* (X-shaped form), *os wormii suturae lambdoidea*, *os postsquamosum*, *sutura palatine* (straight form) and *canalis craniopharyngeus*.

It was observed the loss of all teeth of the upper jaw during the lifetime, except the third right molar, atrophy of the dental cells of alveolar processes. On the lower jaw during the lifetime were lost incisors, first and second molars, second premolar. The mesio-distal (MD_{cor}) and vestibular-lingual (VL_{cor}) diameters of the crowns of the third molars are placed in the category of small and very small meanings (Table 2). On the third molar were fixed unusual powdering of the dental tissue (Fig. 3). On the left molar is seen enamel drop ("pearl"), which represents excessive formation of the dental tissue during the process of its development and is placed on the root of the molar (Fig. 3).

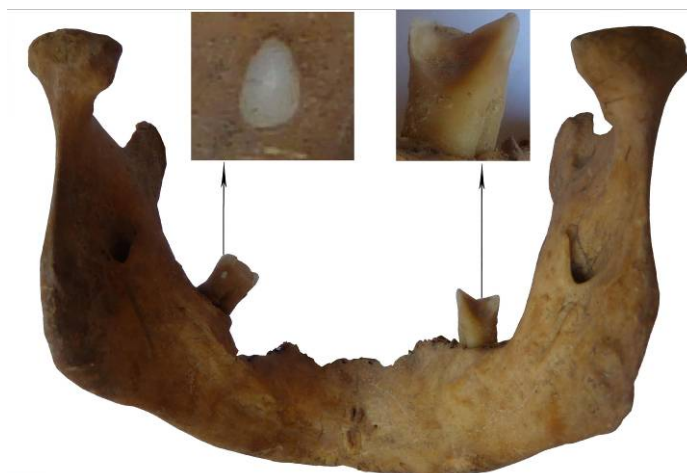

Fig. 3. Enamel pearl on the left third molar and unusual powdering of the dental tissue on the right third molar

Weak signs of porotic hyperostosis of eye sockets (*cribra orbitalia*, score 1) and in the area over the outer ear canals is observed. It is well known that porotic hyperostosis appears as a result of compensatory response to the decline of hemoglobin in the blood.

On the left part of the skull, in the area of parietal and occipital bones is fixed a depressed and healed fracture left after a blow inflicted by some blunt object. The diameter of the bone defect is 34×18 mm, the edge is sharply expressed. Close to the lambda is seen a crack of semi-circular form, as a result of the blow of some blunt object. Dimension of the crack reaches 42 mm.

Ossification of the larynx is also fixed. The anatomy of larynx is a complicated complex of muscular and cartilage tissues, blood and lymph vessels, nerve endings. As it is known, after 30 happened deposits of calcium salts which provokes ossification and loosing of mobility. Ossification of larynx also could be connected with the spread of different infectious diseases (Fig. 5). This leads to the worsening of voice ability – the speech becomes deaf and rattling.

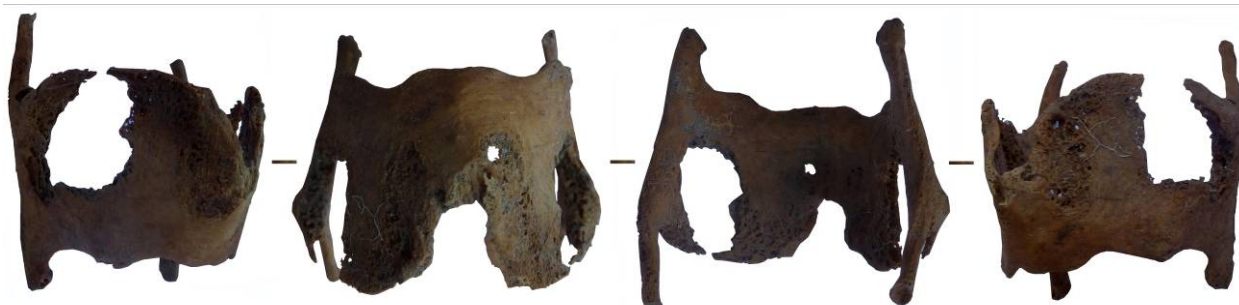

Fig. 4. Ossification of trachea

On the left parietal bone are discovered two osteomas. Dimensions of the first is 11×9 mm, the second one – 5×6mm. Osteomas are very dense formations with smooth surface and their structure do not differ from normal bone tissue.

Individual N 2. The remains belong to male who had died at the age of 40-49. The artificial frontal-occipital deformity of the head is observed. The form of the skull in the vertical norm corresponds to the sphenoid variant (Fig. 5).

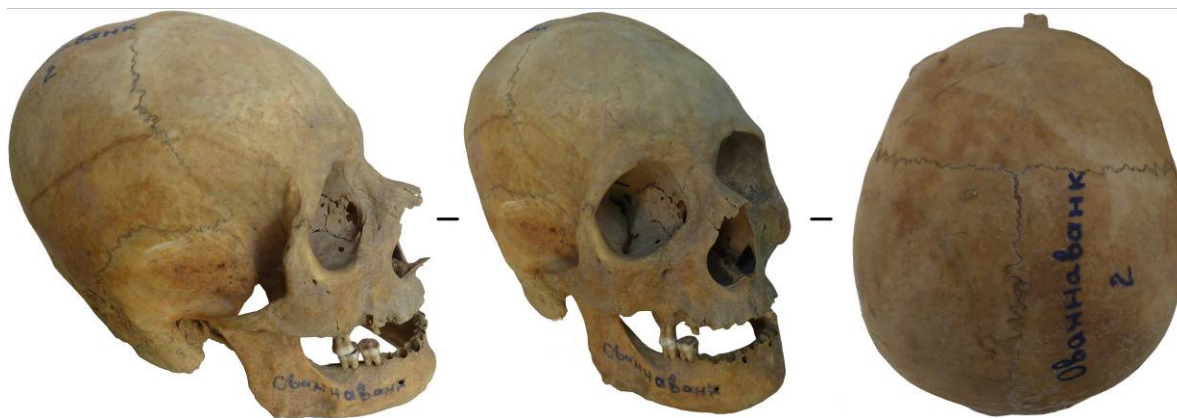

Fig. 5. Individual N. 2.

The brain box is characterized as mesocranial, with very small longitudinal and transversal diameters, medium – highrise (Table 1). The height of the skull is hypsicranic and acrocranic. Width of the forehead and occiput is medium. The relief of the lower edge of frontal scales is poorly developed (score 1), the degree of glabella's performance is estimated as score 2. The face is orthognathic, high and medium-wide, orbits are high and wide, height and width of the nose – very big.

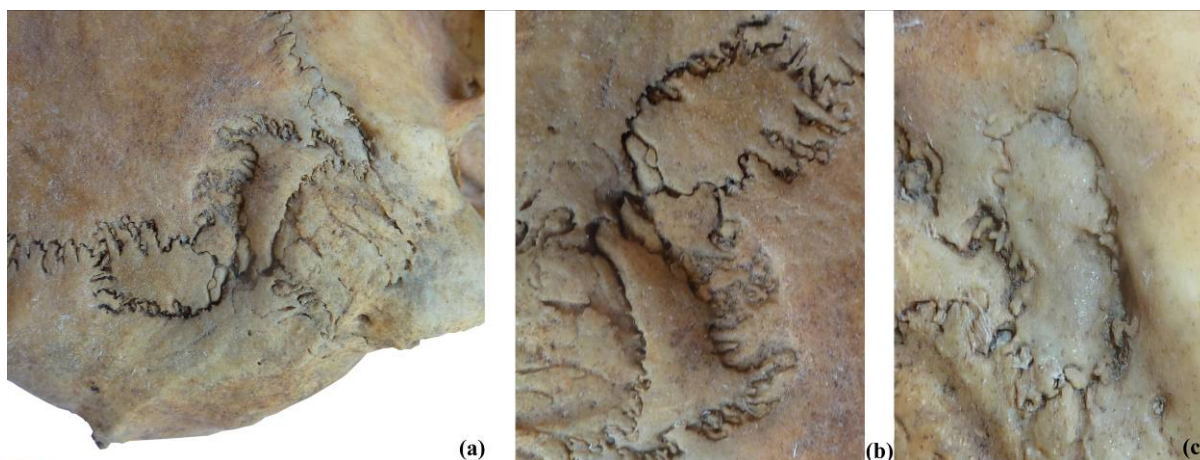


Fig. 6. Additional bones of irregular shape in *os wormii suturae lambdoidea*, in the area of *os asterion*, in the area of parietal notch (*os postsquamosum*)

On the skull are revealed the next discrete-varying features: *foramina zygomaticofacialia*, *foramina mastoidea*, *foramen pterygospinosum*, *foramina mentalia*,

canalis condyloideus, *spina processus frontalis ossis zygomatici*, *stenocrotaphia* (X-shaped form), *processus frontalis squamae temporalis*, *os postsquamosum* (Fig. 6c), *os wormii suturae lambdoidea* (Fig. 6a), *os asterion* (Fig. 6b), *os Incae incompletum* (Fig. 8), *os zygomaticum bipartitum*, *sutura palatine* (П-shaped form), *sutura incisive*, *canalis craniopharyngeus*, *processus paramastoideus*.

The form of individual's occlusion is labiodontic. Had been observed the loss of molars during lifetime (M^1 , M^3 /right/, M^1 , M^3 /left/, M_1 , M_3 /left/). The mesio-distal (MD_{cor}) and vestibular-lingual (VL_{cor}) diameters of the crowns of the second and third molars are classified as belonging to the small and very small meanings (Table 2). On the right premolar is fixed pathological erasure of the dental tissue, probably caused by abnormal load on the dental apparatus. The hypoconus of the second upper molars is reduced. 4-tubercle forms are marked on the lower first and second molars. On the lower second molars is marked the Y type of pattern.

The defect of tooth enamel (enamel hypoplasia) is fixed on the right molar. Enamel hypoplasia speaks in favor of sudden stressful effects experienced by the individual during childhood (as a rule, in the interval between 6 months to year 7). Traces of odontogenic osteomyelitis (alveolar abscess) is seen on the right side of the upper jaw in the area of the second premolar and first molar, on the left side – in the area of the canine tooth, first and second premolars, on the lower jaw, in the area of the second canine teeth. Alveolar abscesses could be provoked by paradontitis, traumas and pulp necrosis. Tartars are fixed almost on all teeth.

On the right side of the frontal bone has been found shallow, oval shaped depressed fracture ($11 \times 7 \text{ mm}$). Probably, it was a result of healed trace of injury received by the blow of blunt instrument. On the frontal bone exists a cut made by sharp instrument (4.5mm long) (Fig. 7). The male has a trauma of nasal bones.



Fig. 7. Symbolic trepanation

On the parietal bones has been found traces of specific actions. These are numerous long and narrow damages of thin bone plate made of a tool with sharp cutting edge. Such manipulations made on the skull are result of the symbolic trepanation. Symbolic trepanation is a superficial (blind) one which slightly disturbs integrity of

calvaria (Fig. 7). These scars on the parietal bones of the individual could appear during some ritual.

In the ear canals are mentioned osteofitic formations. The presence of osteofitic formations is connected with the tension of periosteum and formation of new osteogenesis under the influence of cold water which enhances the narrowing of blood vessels in the ear canal.

Individual N.3. The remains belong to young woman who had died at the age of 18-22. In the vertical form the skull corresponds to sphenoid variant (Fig. 8). On the skull is fixed artificial frontal-occipital deformation.

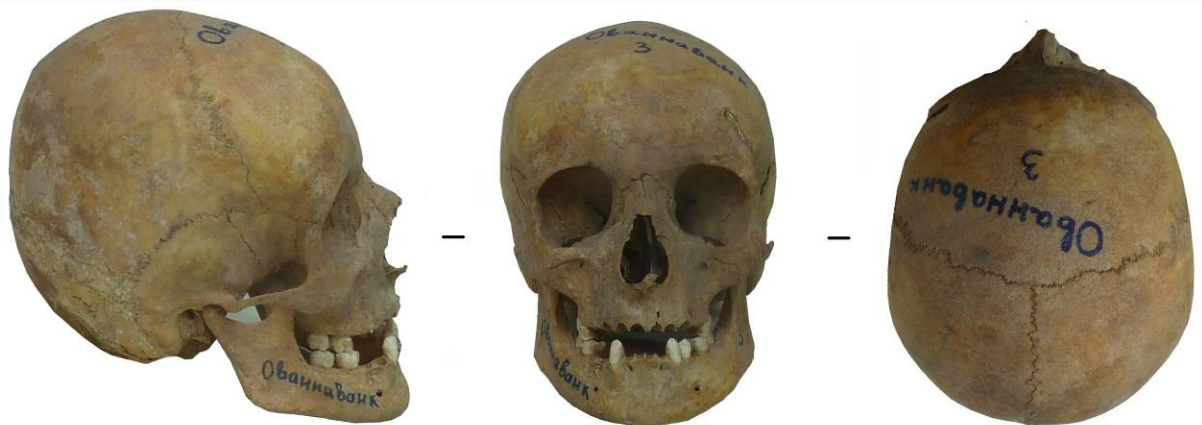

Fig. 8. Individual N. 3.

The skull of the individual is characterized as brachycranic with large transversal, small longitudinal and very big height diameters. The height of the skull is characterized by hypsicrany and acrocrany. Relief of the lower edge of scales of the frontal bone is poorly developed. Brow ridges represent barely visible elevations from right and left of glabella (score 1). The width of the face is very big, width of the back of the head - big. The outer occipital protrusion is poorly developed and in the lateral norm the back of the head is rounded. The face is orthognathic, high and medium wide, orbits are high and very wide, the nose is narrow and high. The length of the lower jaw is medium-sized. Tuberosity in the area of outer and inner surfaces of edges (the place where muscles *m. masseter* and *m. pterygoideus medialis* are attached) of lower jaw is expressed weakly. The body of the lower jaw is very low and thick.

On the skull are observed the next cranioscopic features: *foramina zygomaticofacialia*, *foramina parietalia*, *foramina mastoidea*, *foramina mentalia*, *canalis condyloideus*, *spina processus frontalis ossis zygomatici* (projecting form), *processus frontalis squamae temporalis*, *processus temporalis ossis frontalis*, *os wormii suturae lambdoidea*, *os asterion*, *stenocrotaphia* (X-shaped form), *sutura palatine* (П-shaped form), *sutura incisive*, *condylus occipitalis bipartitum*, *processus paramastoideus*.

The form of the alveolar arc is U-shaped. Among molars (upper and lower) is absent the last one – third. Mesiodistal and vestibular-lingual dimensions of the first and second lower molars are classified as small meanings, and mesiodistal and vestibular-

lingual dimensions of the first and second upper molars fall into the category of medium and big (Table 2). Was calculated the amount of the third step-index which regarding the width of the crown (VL) constitutes 101.86. The hypocones of the first molars is weakly reduced (score 4), and also the metacones (score 2), but the second molars are completely reduced (score 3). Lyre-shaped form of the first furrow of paracones (type 3) is observed on the first upper molar. First lower molars are five-cusped, and the second ones - four-cusped. On the first lower molar we found the average additional bump between the metaconid and entoconid (TAMI). Hypoplasia of enamel is fixed on the canines (Fig. 9), first premolar (P_1), and second molar (M_2).

Porotic hyperostosis is fixed in the area of outer ear canals, and osteofitic formations in the ear canals as well. The woman has also several *traumatic disorders* on her skull. Were fixed damages of nasal bones characteristic for blows made by some blunt tool. On the left side is seen a crack. Features of inflammation in the damaged area are not fixed. The damage is a result of a blow from the left, i.e. the woman had stepped slightly back and to the left in order to avoid it. Has been observed also a violation of anatomical integrity of the hole of medial cutter. The damage is represented in the form of a crack. In that case the damage could have been the result of an unusually strong impact on the tooth, for example, gnawing (or nibbling) of solid food. On the left side of the frontal bone are fixed effects of a cutting blow (29 mm. long), made by a tangent strike which probably became lethal for the individual.

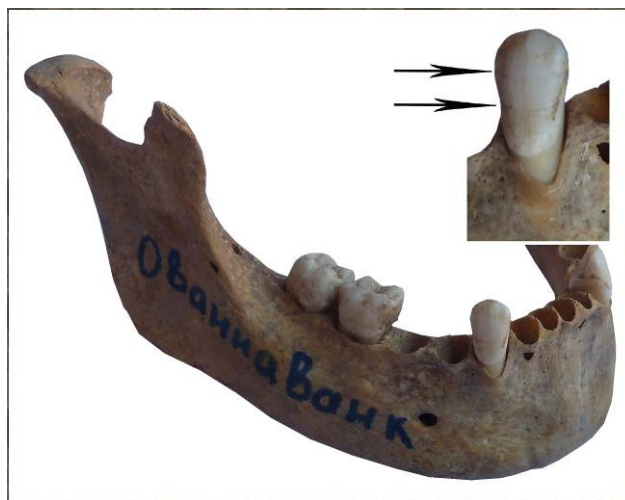


Fig. 9. Enamel hypoplasia

Individual N. 4. The remains belong to male who had died at the age of 50-55 (Pic. 10). On the skull is fixed an artificial frontal-occipital deformation. The braincase of the individual is characterized as brachyranic, with medium size transversal and very small longitudinal diameters. It is medium high, by the altitude of the transversal index – hypsicranic. The value of altitude-longitudinal index is characterized as metriocranic. The forehead is narrow and the back of the head – wide. The face is prognathic, high and medium wide, orbits are high and medium sized, the height of the nose is big, width – narrow.

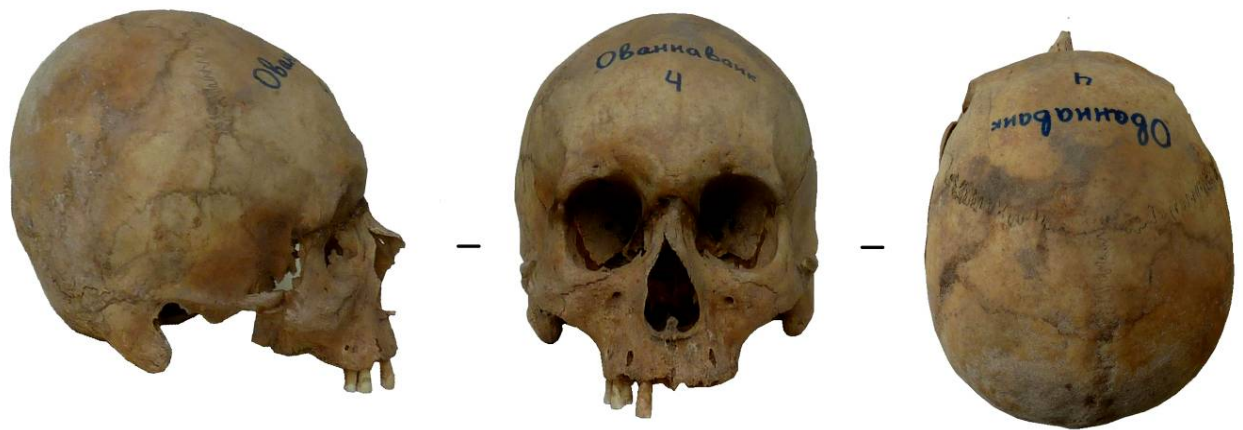

Fig. 10. Individual N 4.

On the skull are revealed the next discrete-variable features: *foramina zygomaticofacialia*, *spina processus frontalis ossis zygomatici* (protruding form), *stenocrotaphia* (X-shaped form), *processus frontalis squamae temporalis*, *processus temporalis ossis frontalis*, *os epiptericum*, *os wormii suturae squamosum*, *os wormii sut. occipitomastoideum*, *sutura palatine* (П-shaped form), *sutura incisive*, *canalis craniopharyngeus*, *processus paramastoideus*.

The mesio-distal (MD_{cor}) and vestibular-lingual (VL_{cor}) diameters of the first and second molars belong to the category of small and medium values (Table 2). The development of edge-ridges on the upper lateral cutters has been observed. The parodontosis was also fixed (M^2). The traces of odontogenic osteomyelitis (*alveolar abscess*) are seen on the right side of the upper jaw, in the area of M^1 , and on the left side - M^2 . Hypoplasia of enamel is fixed on the second cutter (I^2) and canine (lower jaw). The loss of molars during the lifetime has been observed (M^1 , M^2 , M^3 /right/, M_1 , M_2 , M_3 /left/, M_3 /right/). Dental calculus is fixed on the studied teeth.

On the skull are fixed several traumatic disturbances: 1. Injury caused by blunt objects on the right part of the parietal bone (dimensions of the injury are 14×10.5mm. and 5×4mm.), 2. Injury caused by blunt object on the left part of the parietal bone (dimensions - 6×5mm.), 3. Lacerations on the supraorbital area of the face caused by blunt object.

On the skull were revealed porotic hyperostosis on the forehead and in the area of outer ear canals, and exostoses in the ear canals as well.

Individual N. 5. Remains belong to a woman at the age of 30-50 years. The skull is badly preserved, it misses facial skeleton and part of the frontal bone (Fig. 11). On the skull is seen an artificial frontal-occipital deformation. The transversal diameter of the braincase belongs to the category of very big, and the height diameter – of small. The height of the skull is characterized as tapeinocranic. The width of the back head is large.



Fig. 11. Individual N. 5.

On the skull are revealed the next discrete-variable features: *os postsquamosum*, *foramina parietalia*, additional bones of irregular shape in the lambdoid suture (*os wormii suturae lambdoidea*), *foramina mastoidea*, absence of *foramina spinosum*, *processus paramastoideus*, *canalis condyloideus*, *mendose suture (sutura mendoza)*.

On the right of the mastoid process is fixed surface disturbance of the external compact (3×3 mm.). The depth of the hole is 3 mm. In the area of the injury are traced elements of sclerosis of the edges of injuries. On the skull were revealed porotic hyperostosis in the area of external ear canals, and exostoses in the ear canals.

Individual N. 6. The skull is in a fragmentary condition, it misses frontal bone, facial skeleton (Fig. 12). Remains belong to a male who had died at the age of 35-39. He has medium-sized transversal diameter of the braincase and narrow back head.



Fig.12. Individual N. 6.

On the skull were revealed the next discrete-variable features: *stenocrotaphia* (X-shaped), *processus frontalis squamae temporalis*, *os wormii suturae squamosum*, *os postsquamosum*, *foramina parietalia*, *os wormii suturae lambdoidea*, *foramina mastoidea*, *canalis condyloideus*.

Of 32 permanent teeth was preserved only the upper right canine, vestibular-lingual diameter VL_{cor} of which is 8.1mm and mesio-distal diameter of the neck MD_{col} is 6,5mm. On the canine is seen a weak form of hypoplasia of enamel and dental calculus.

On the skull were revealed occipital structures (the development of tubercles on the occipital torus is good (TOT: score 2), that of retromastoid processes is small (PR: score 1). Structures located at the origin of the upper trapezius muscles are referred to as tubercles on the occipital torus (TOT) and those located where the superior oblique muscles insert (below the inferior nuchal line and lateral to the *rectus capitis* muscles) are known as retromastoid processes (PR). The formation of occipital structure is a response of the organism to physical load, chronic (multiple) microtraumas²². Had been observed also osteoarthritis of maxillary joint. Modern science regards osteoarthritis as a disease of an unknown ethiology and studies different endogenous and exogenous risk factors. The development of osteoarthritis could be the result of a single injury, intra-articular fracture and inflammation. Porotic hyperostosis is seen near the ear canal and on the parietal bones. Also is registered exostosis near the ear canal.

Individual N. 7. Fragments of the skull belong to a 4-5 years old child. On the bones were revealed the next discrete-variable (non-metric) features: *os wormii suturae squamosum*, *foramina parietalia*, *os Incae* (Fig.13), *os wormii suturae lambdoidea*, *os asterion*, *foramina mastoidea*.



Fig. 13. *Os Incae multipartitum*, *foramina parietalia*

The tubercle of Carabelli is seen on the first upper molar, and the reduction of hypocones misses (M1). The first lower molar is quinetubercular with the Y-type ornamentation.

Individual N. 8. Fragments of the skull belong to a 2-3 years old child. On the bones of the skull are revealed the next discrete-variable features: *foramina zygomaticofacialia*, *os wormii suturae squamosum*, *os wormii suturae lambdoidea*, *condylus occipitalis bipartitum*.

The porousness and porosis is observed on the bones of the postcranial skeleton (particularly in the area of epiphysis of the humerus) (Fig. 14). The morphological

²² Khudaverdyan 2016: 104-105.

picture is characteristic for the local ossification of hemorrhage (i.e. hemorrhage which lasted for some period). The differential diagnostics of this palaeopathology could include infectious disease or vitamin deficiency.

On the left parietal bone are discovered traces of inflammation in the form of *dura mater* on the inner plate (epidural hematoma) (Fig. 14). Around the defect was mentioned the existence of the destruction of cortical layer.



Fig. 14. Cribrotic changes on the surface of humerus

Endocranial pathologies fixed on the remains of the child are result of inflammation or hemorrhage of the meninx and are connected with the wide spectrum of diseases (tumor, tuberculosis, meningitis, syphilis, secondary infection of the meninx, vitamin deficiency of A, C and D etc.)²³.



Fig. 15. Subepidural hematoma on the inner side of the right parietal bone

Individual N. 9. Fragments of the skull belong to a 1.4-1.6 year old child. On the bones is seen only *foramina mastoidea* (discrete-variable feature). Inflammation of the right mastoid process of the temporal bone (mastoiditis) is visible on the skull.

²³ HersHKovitz, Greenwald, Latimer, Jellema, Wish-Baratz, Eshed, Dutour, Rothschild 2002: 201–216; Lewis 2004: 82–97.

Thus, the individuals under study (NN 1, 2, 3, 4, 5) had artificially deformed heads (Fig. 16, 17). The change of the size and form of the calvaria speaks in favor of inborn or gained deformations. Gained deformations could be natural, i.e. consequences of a disease (plagiocephaly, rachitis, acromegaly etc.), and artificially caused. Hippocrates describes this custom among peoples residing along the shores of the Black and Azov seas. Depending on the methods of intentional deformation and spread of deformational impacts on the skull bone, Y.W. Zhirov²⁴ had suggested the next classification of the types of deformation: annular which in its turn is divided into high (with frontal-occipital level of deformational impacts) and low (when the compressive bandage is located on parietal bones or in the parietal-occipital area and lower jaw), frontal-occipital, parietal and occipital. But also numerous transitional types of deformation are registered.

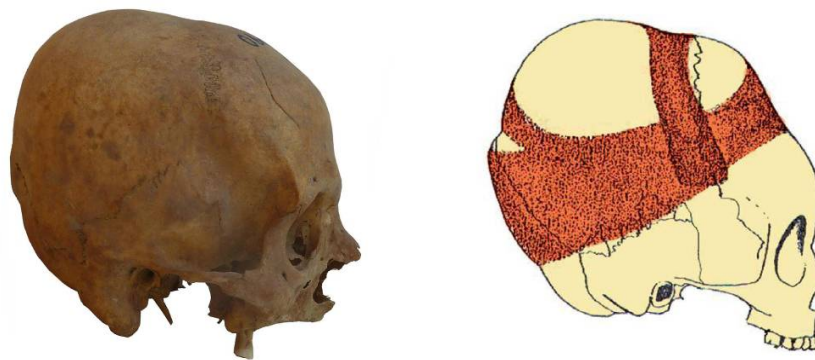


Fig. 16. Artificial deformation of the head (Individual N. 1)

In Hovhannavank are represented two types of deformation: annular parietal-occipital high type and annular parietal-occipital which comes near to the cone by form. In the case of the first type the parietal bone is straightened and elongated upwards, the occipital bone is flattened and does not have corresponding deflection and also is stretched upwards (individuals 1, 2, 4, 5, Pic. 16). From the pressure of the circular bandage on the parietal bones are registered traces of wide flattened strip, and a shallow groove on the occipital bone. In the second type the parietal bone is inclined from the backside and stretched upwards, occipital bone is flattened and stretched upwards, and parietal bones are convex in the area of the sagittal suture (individual 3, Pic. 17). The means and methods used for the desired form, degree of the expression of the skull deformation were diversified. Were used bandages, gauzes, kerchiefs, overlays made of wood, bone, or stones. Among some ethnic groups from the very beginning of life took place the “forming” of the head manually.²⁵

²⁴ Zhirov 1940: 81-88.

²⁵ Dyachenko 1988: 46-49.



Fig. 17. Artificial deformation of the skull (Individual N. 1)

Motives for the intentional deformation of the head could be the next traditions or medical procedures: 1) unintentional action of some household item (special type of a cradle which brings to a flattening of the occipital bone), 2) underlining the social status and distinction from foreign groups, 3) correction of “irregular” form of the skull and desire to get “beautiful” form of the head which satisfies the aesthetic norms, 4) a possibility to change personality type of an individual, 5) necessity to stop rapid growth of the brain matter, 6) a desire to accelerate the process of the overgrowth of fontanel, 7) the result of a massage (to remove headache), 8) a desire to protect the head of the newborn from natural factors (frost, wind, heat).²⁶

The character and location of injuries on the skull indicates on the social background where this or that dangerous situations could occur. Thus, anthropological materials should be regarded as independent sources during archaeological reconstructions performed in the course of archaeological investigations. Injuries with traces of the healing of the bone tissue occur in the case of four individuals. Injury with lethal outcome was found by one individual (N 3, ♀ 18-22 year old). To the category of facial injuries could be refer to: healed fracture of nasal bones (N 3, ♀ 18-22 year old; N 2, ♂ 40-49 year old), damage of the upper jaw (N 3, ♀ 18-22 year old) and suborbital region (N 4, ♂ 50-55 year old; N 2, ♂ 40-49 year old). Injuries of nasal bones were received by the blow from the left, i.e. individuals were trying to escape, retreated slightly backwards and to the right. The damage of lower jaw resulted from blow on the face in the area of frontal teeth. And the injuries in the area of suborbital region were received by contacting blow from the right, i.e. the people could not react to the blow. To another variant could be classified depressed damage by the blow of some blunt object on the left side of the parietal bone (N 2, ♂ 40-49 year old). Traces of healing and the absence of features of inflammatory process testify that injuries were received long before the death of individuals. In another case the oblong scar (N 3, ♀ 18-22 year old: length of the scar – 29mm; N 2, ♂ 40-49 year old: length of the scar - 4.5mm) made by

²⁶ Popov, Chikasheva, Shpakova 1997: 58; Khudaverdyan 2005: 91-95; 2011a: 602-609; 2011b: 39-41.

a tool having sharp cutting edge was found on the left side of parietal bone. On two individuals are seen fractures made by blows of some blunt object (N 1, 45-55 year old, N 3, ♀ 18-22 year old). Two other variants of damages are different from previous locations: they are detected on the parietal bones and on the mastoid. In the case of a male (N 4, 50-55 year old) and two females are seen traces of healed fractures of parietal bones (N 1, 45-55 year old, N 5, 30-35 year old). On these skulls were fixed impressions of the upper plate of the parietal bone from the right side, on two of them (N 4, ♂ 50-55 year old; N 5, ♀ 30-35 year old) also had been traced defects on the left side. On the right mastoid of the female (N 5, ♀ 30-35 year old) there is a surface disturbance of external compact (3×3 mm). The depth of the fossa is 3 mm. In the area of the damage are seen elements of sclerotization of the edges of injury.

In the group under study were revealed high rates of occurrence of pathology as porotic hyperostosis. By one grownup individual (N 1, ♀ 45-55 year old) was fixed porotic hyperostosis of eye sockets (*cribra orbitalia*). According to some palaeopathologists, *cribra orbitalia* in most cases is associated with deficiency anemia which is developed during chronic course of infective and parasitic diseases.²⁷ Porotic hyperostosis of bones of calvaria was fixed on 6 skulls (N 2, ♂ 40-49 year old; N 3, ♂ 18-22 year old; N 4, ♂ 50-55 year old; N 5, ♀ 30-35 year old; N 6, ♂ 35-39 year old; N 8, 2-3 year old child). Some scholars think that these pathologies on the bone remains are connected to each other.²⁸

Benign tumors were found by some individuals. On the left parietal bone of one individual (N 1, ♀ 45-55 year old) were revealed two osteomas. Osteoma is a benign tumor which occurs after serious injury, infectious disease etc. In the ear canals of 6 individuals (N 2, ♂ 40-49 year old; N 3, ♂ 18-22 year old; N 4, ♂ 50-55 year old; N 5, ♀ 30-35 year old; N 6, ♂ 35-36 year old; N 8, 2-3 year old child) were registered exostoses. The appearance of exostoses is connected with the tension of periosteum and formation of new osteogenesis under the influence of cold water which fosters the vasoconstriction in the ear canal.

By the child (N 9, 1.4-1.6 year old) the study reveals inflammation of the right mastoid of mastoiditis. Inflammation of cells of the mastoid process more often appears as complication of sharp purulent inflammation of the middle ear. By mastoiditis bacteriums enter from the middle ear into the cells of mastoiditis where the inflammation results in the destruction of bone structures.²⁹

Traces of local hemorrhage (ossification of hemorrhage) which were found on the surface of postcranial skeleton of a child (N 8, 2-3 year old) could point on the lack of vitamin C in the food (i.e. children's scurvy). By this child was detected inflammation in

²⁷ Ortner, Putschar 1981; Larsen 1997.

²⁸ Ortner, Putschar 1981.

²⁹ Nussinovitch, Yoeli, Elishkevitz, Varsano 2004: 261-265.

the form of *dura mater* on the inner plate of the skull which, probably, has hemorrhagic character. Traces of injuries during lifetime capable to lead to the appearance of hemorrhage process on the inner surface of the calvaria bone has not been found which excludes the probability of inflammation due to an injury. Possible causes of this pathology could be scurvy, bacterial or virus meningitis etc.

The enamel hypoplasia speaks in favor of a sharp stress which the individual had experienced during childhood (as a rule, between 6 months until 7 year). The effect of the tooth enamel has been detected by three individuals (N 2, ♂ 40-49 year old, N 3, ♂ 18-22 year old, N 4, ♂ 50-55 year old). More often this feature is fixed on the canines, premolars, and cutters. By two individuals (N 1, ♀ 45-55 year old, N 4, ♂ 50-55 year old) was fixed parodontosis. Causes of this disease could be different factors: infectious diseases, eating disorder, metabolism, disorders of the endocrine system, age factor, violation of vitamin balance, poor oral hygiene, food rich of carbohydrates, different anomalies of teeth growth, complications occurring during pregnancy.³⁰ Parodontosis has been detected in the area of molars (M²: N 4, ♂ 50-55 year old; M₁ и M₂: N 1, ♀ 45-55 year old). Dental calculus is fixed by three individuals (N 1, ♀ 45-55 year old, N 2, ♂ 40-49 year old, N 4, ♂ 50-55 year old). It was established that dental calculus and parodontosis are accompanying each other pathologies of the dental system.³¹ Traces of odontogenic osteomyelitis (*alveolar abscess*) has been found by two individuals (N 2, ♂ 40-49 year old, N 4, ♂ 50-55 year old). Alveolar abscess is seen by the 50-55 year old male (N 4) on the right side of the upper jaw, in the area of the first molar (M¹), and on the left side, in the area of the second molar (M²). By the second individual (N 2, ♂ 40-49 year old) this feature is fixed on the upper jaw (on the right side, in the area of the second premolar (P²) and first molar (M¹), on the left side of the canine (C), first and second premolars (P¹, P²), and on the lower jaw, in the area of the lateral cutter (I₂: from both sides). Alveolar abscesses could be provoked by parodontosis, injuries and pulp necrosis. By the male aged 40-49 (N 2) is fixed pathological the wear of dental tissue (P² /right/), probably, caused by abnormal load on the dentoalveolar apparatus or anomaly of malocclusion. Premature abrasion of enamel and dentine could be conditioned by the diet which includes hard and coarse-grained food. The lost of the teeth during lifetime is seen by three individuals (N 1, ♀ 45-55 year old, N 2, ♂ 40-49 year old, N 4, ♂ 50-55 year old). More often were lost molars.

Below we shall present summarized anthropological (craniometric, cranioscopic, odontological) characteristics of individuals from Hovhannavank. The skulls of males have brachycranial braincase with very small longitudinal, small transversal, medium height diameters. The height of the skull is characterized by hypsicrany and acrocrany. The face is mesognathic, medium wide, high, medium flatness of horizontal profile. Orbits are medium wide and high, and are characterized by gipsikonkh altitude and

³⁰ Hillson 1986; Larsen 1997.

³¹ Hillson 1986.

latitude indicator. The nose is high and wide, the palate is narrow, medium wide. Remains of the woman are characterized by general gracile complexion, with very poorly expressed relief in the area of brow. The braincase is brachycranial, with small longitudinal, big transversal, big height diameters. The height of the skull is characterized by hypsicrany and metriocrany. The greatest width of the forehead is very big, the smallest width is big. The face is orthognathic, medium high and medium wide, orbits are high and wide, the height of the nose is big, width - medium. Comparison of the dispersions reveals essential increase of variability of 32 features and indicators.³² Plausible prevalence of empiric dispersions are fixed only through 8 features and indicators: 46, 60, 62, 9:45, 77, <zm, 52:51, 52:51a.³³

On the skulls is seen high frequency of the next cranioscopic (discrete-variable) features: *os zygomaticum bipartitum*, *foramina mandibularia*, *stenocrotaphia* (X-shaped form), *spina processus frontalis* (protruding form), *os wormii suturae lambdoidea*, *os wormii suturae squamosum*, *sutura incisive*, *canalis condyloideus*, *processus paramastoideus*, *processus frontalis squamae temporalis*, *processus temporalis ossis frontalis*, *foramina mastoidea*, *foramina parietalia*, *os asterion*, *condylus occipitalis bipartitum*. The population is characterized by moderate and low frequency of occurrence of *foramina supraorbitalia*, *foramina infraorbitalia*, *foramen pterygospinosum*, *os Incae completes*, *os postsquamosum*, *sutura mendoza*, *foramen spinosum inco*.

The odontological complex characterizes individuals as representatives of the "western" odontological tree. The obtained results are evidence of the prevalence of the psalidodonta form of occlusion by the population. By one individual occurs labiodontic form. Diastemas between upper medial cutters were not found. General frequency of occurrence of crowding in the group is 33.34% (1/3). On lateral cutters of spade-shaped form were fixed only by one individual. The reduction of hypoconus on the second upper molars has been found by 66.67% of subjects (2/3). The occurrence of Carabelli tubercle equals to 33.34% (1/3). The form 3 of the first furrow of paracone on the first upper molar has been observed by one individual. Six-cusped forms on the first lower molars are missing, five-cusped forms are characterized by high frequency of occurrence (75%, 3/4), four-cusped forms are fixed by one individual. Bicipital grooves on the first lower molar fix high frequency "Y" type of the pattern. Four-cusped forms of the second lower molars were revealed by two subjects (66.67%, 2/3). Bicipital grooves on the second lower molar fix the "X" type of the pattern. On the lower jaw actually are completely missing signs of the eastern odontological tree. Protostylid, distal crest of trigonitis, 6-furrowed first lower molars, knee crease of metacone are absent. The inner middle additional furrow on the first lower molar was fixed by one individual. Variant "2" of the second furrow of metacone also appears by one subject.

³² Alekseev, Debets 1964.

³³ Khudaverdyan, Zhamkochyan, Hakobyan 2016: 13-21.

Craniological data also was subject to cross-group statistical analysis³⁴. The comparative background chosen for the analysis includes the territory of the Caucasus, Middle East, and South-Eastern Europe (Table 3).

On the *first phase* of the cross-group analysis was constructed a model on the basis of data regarding the 14 dimensions of the skull and face (Table 4) in the 75 groups from the Caucasus and South-Eastern Europe. On the Picture 18 is represented the place of the groups under study in the space of I and II canonic vectors (CV). The first CV (29.97% of general variability) divides the studied groups by the complex of features of which the ratio of longitudinal and transversal diameters of the skull and the width of the neck are basic ones. At CV I the series from Kabardino-Balkaria (43, 42), Northern Ossetia (44), Dagestan (31, 28), Georgia (13), Azerbaijan (17, 18), Volga-Ural (61–66, 74, 70, 72), Ukraine (92) demonstrate maximum meaning and are concentrated in the positive field of variability in the right part of the chart. Almost all are characterized by mesocrany and brachycrany, wide and high faces. In the negative field of variability are localized series from Dagestan (30, 29), Azerbaijan (14–16), Armenia (2, 6), North-Western Caucasus (60), Northern Ossetia (47), Danube-Dniestr region (94), Western Ukraine (93), Krasnodar district (33, 35, 38), Volga-Ural (68, 85, 83), and Karachai-Circassia (41, 39).

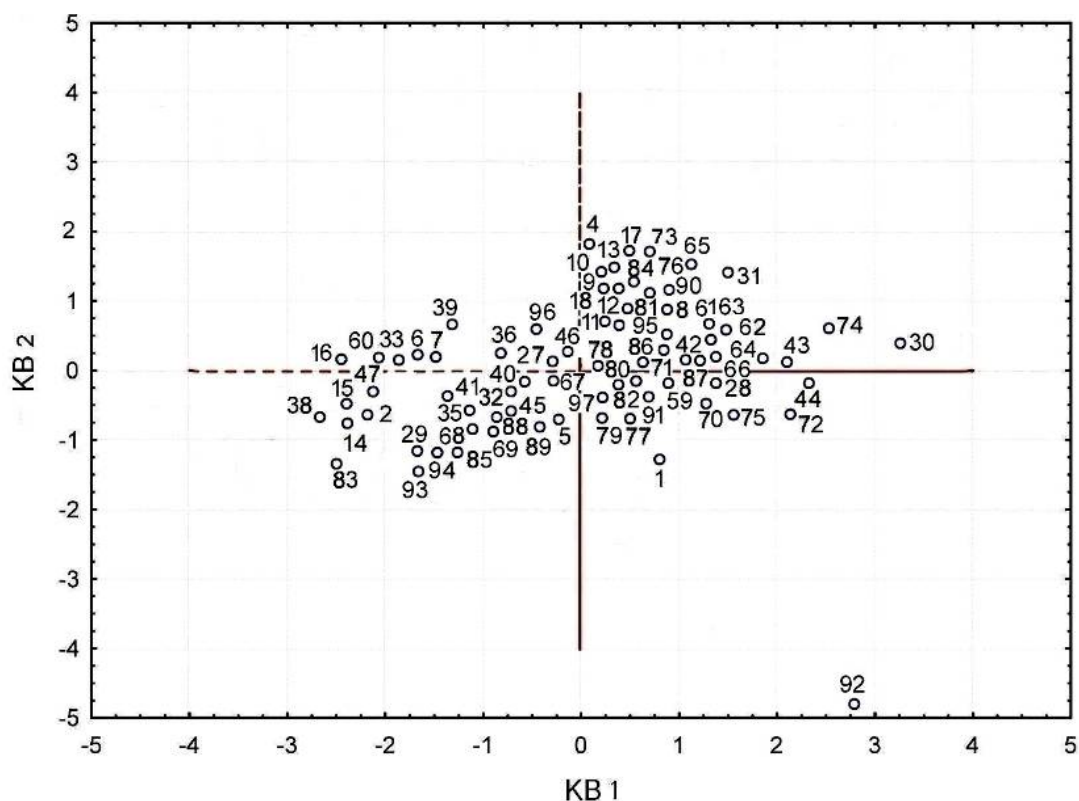


Fig. 18. The place of male craniological series in the space of the first and second canonic vectors.
Numbers of series according to Table 3.

³⁴ Khudaverdyan, Zhamkochyan, Hakobyan, Babayan, Yengibaryan, Khachatryan, Yeganyan 2018: 78-84.

Samples from the catacomb burials of Mingeaur (14, 15) and the series from Armavir (2) demonstrate greatest similarity. The mentioned skulls mostly are dolichocranic, medium high, faces are medium wide and greatly profiled, eye sockets are medium high, nose is greatly protrusive. Is traced some similarity of the mentioned series with the groups from Northern Ossetia (47) and Krasnodar district (38). Skulls from Garni (5) and from the stone mausoleum of Middle Volga (89) are placed quite compactly. They are united by the medium high, narrow and greatly profiled face on the nasal-molar level.

In CV II (23% of variability) the largest load lays on the height of the orbit. The place of the analyzed groups in the space of the second vector-discriminator shows high positive size by the groups from Middle Volga (84, 65, 90, 76, 73), Dagestan (31), Georgia (9, 10, 12, 13), Azerbaijan (17, 18), and Armenia (4).

The Hovhannavank serie (4) reveals similarity with the Caucasioni groups from Georgia (10, 13, 12, 9). To them adjoin individuals from Christian and Muslim burials from Mingeaur. Therefore, the craniological serie from Hovhannavank (4) distinguishes intra-group heterogeneity. Differences in the morphological characteristics of the skulls are quite clearly observed visually for the male samples and for females. As it was mentioned above, for some features were revealed heightened meanings of the standard deviations. To the latter belong the width of the face (46, 45), height of the palate and alveolar arch, angles of the horizontal profiling of the facial skeleton, and orbital and frontal-zygomatic markers as well. Besides that by the five individuals were fixed horizontal zygomatic bone suture (*os zygomaticum bipartitum*), by two individuals - the Inca bone (*os Incae*), by one - the form 3 of the first furrow of paraconus on the first upper molar. On the typological similarity of Chevsur and Dusheti series with the Mingeaur groups was indicated by M.G.Abdushelishvili still in 1964.³⁵ In one cluster with the Hovhannavank (4) and Caucasioni groups of Georgia (10, 13, 12, 9) falls the serie from the cemetery near the building of the Greek palace (73). It is known that this necropolis belonged to the residents of the Armenian colony of the city of Bulgar, and the hyperbrachyranic of Caucasoid type male skulls of this serie, according to T.A.Trofimova,³⁶ almost by all features are comparable with the series of modern Armenian skulls.

The comparison of 51 female series was undertaken by 14 main features (Table 5). It appears that in the first CV (represents 43.854% of overall variability) greatest loads fall on the height dimensions of the face (52, 55, 48). In the space of CV I by high positives are characterized groups of Southern Caucasus (4, 7, 18, 9, 19), Northern Ossetia (48), and Volga-Ural (74, 87, 90, 66), and that of the negative - groups of

³⁵ Abdushelishvili 1964: 22.

³⁶ Trofimova 1956: 85-88.

Chigirin (92), Majar (59), Gamovski and nearby gorges (32). The Caucasioni morphological complex which is present among the series of Georgia (8–10), gets closer to the group from Pamyatnij znak (87)(Pic. 19). Among the series related to series mentioned above is that represented by the samples from the burials of Muslim type from the Samukh region of Azerbaijan (18). The skulls are mostly brachycranial, along with high, slightly profiled facial skeleton and high eye sockets. From the overall picture “is distinguished” the brachycranial serie of Hovhannavank (4). The craniological serie most strongly is distinct from other materials on the territory of Southern Caucasus and demonstrates other complex craniological peculiarities.

For the CV II (21.46% of the overall variability) became defining transversal, longitudinal diameters, the angle of the nasal bones. On the plane of the II vector-discriminator the high negative values were found by the skulls from the cemeteries of the Astrakhan district (66, 64), Middle (86, 90, 74, 78) and Lower Volga region and Lower Don region (63), Moldova (95), Karachai-Circassia (43), Northern Ossetia (55), and Armenia (4). On the opposite positive pole are grouped series from Northern Ossetia (47–49), Georgia (7), Azerbaijan (16, 14), Armenia (2, 6), Karachai-Circassia (40), North-western Caucasus (60), and Middle Volga (79). The sample from Dvin (1) occurs as statistically more related to the collective serie of Chernyakhov culture from Danube-Dniester region (94). But the latter slightly deviates towards the Mayachnij II group (65) of the Golden Horde period. Mesocranial, orthognathic, strongly profiled skulls with low orbits, medium wide nose characterize the population of Astrakhan district. It is notable that the female serie from Moshshhevaya Balka (60) is related to the earlier group (6) from Armenia. A similar complex of features exists among the population of the catacomb burials from Mingechaur (14). Here the skulls are mostly dolychocranial, medium high, faces are medium wide, strongly profiled, eye sockets are medium high.

On the wide comparative background is particularly visible (Fig. 19) that the greatest similarity exists between synchronous samples from the cemeteries of Garni (5), Upper Chir-Yurt (27) and the early group from Karachai-Circassia (39). In its turn, in this cluster falls the mesobrachycranial, having medium wide or wide face group from the Zhukov site (33) which represents one and the same combination of anthropological features inherent to individuals from the late group of Karachai-Circassia (40).

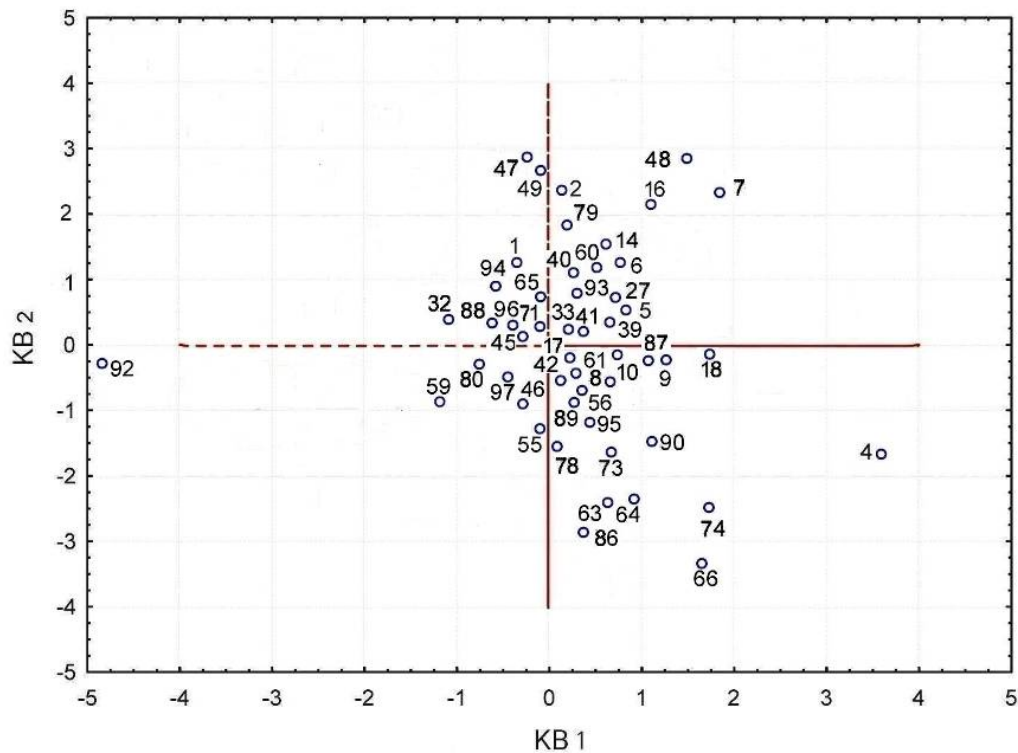


Fig. 19. Place of female craniological series in the space of the first and second canonic vectors.
Numbers of series according to Table 1.

In order to take into consideration ancient Near-Eastern series, we have additionally analyzed our skulls with the reduced set consisting of 10 features (Table 6). First two more informative CV reflect in total 57.654% of variability. The most significant features by CV I (46.8% of overall variability) for the intergroup differentiation of 63 series are the length and width of the braincase. On opposite poles of the intergroup differentiation which describes the first discriminator, appear to be: on the one hand groups from Dagestan (31, 28), Northern Ossetia (44, 55), Kabardino-Balkaria (43, 42), Stavropol district (59), Iran (24, 25), Georgia (8-13), Azerbaijan (17-18), Moldova (95), and Armenia (4), on the other hand – craniological materials from the territory of Israel (26), Mesopotamia (19), Turkey (23), Krasnodar district (38), Circassia (41), Northern Ossetia (47-49), Azerbaijan (14-16), Armenia (6, 2), North-western Caucasus (60), Danube-Dniester region (94), and Western Ukraine (93).

Adding to the analysis new series has not changed substantially the relative position of already used male samples during the first analysis from the territory of Armenia (Fig. 20). But apart from the series of Caucasioni type from Georgia (11, 8) and skulls from the burials of Christian type from Mingechaur (17), in the list of the most closely related samples from Hovhannavank (4) turns out to be the group of Turang Tepe (25) from Iran. At the same time the results of analysis show an anthropological similarity of the mentioned groups with the brachycranial maturized skulls from the cist tomb burials of Kharkha, Daryal gorge (55).

The position of series speaks in favor of the greatest closeness of the Moshshevaya Balka sample (60) to the series from Armenia (6) and Mesopotamia (19). Among the series affiliated to the series mentioned above is the sample from Karachai-Circassia (41). The most massive skulls are those medieval series from Boghazkoi, Turkey (23) which are especially unique and are not similar with other series.

In CV II (10.854% of variability) the greatest load falls on the width of the orbit and height of the nose. The place of studied groups in the space of the second vector-discriminator shows high positive values by the groups from Southern Caucasus (2, 7, 14-16) and Mesopotamia (22). On the surface of the II vector-discriminator high negative values were found by the skulls from Turkey (23), Iran (24), and Armenia (1).

Comparative analysis shows that morphological characteristics of the Armavir serie (2) demonstrates close similarity with the samples of the catacomb burials from Azerbaijan (14, 15, 16). Here the most distant position occupy the artificially deformed skulls from Mingechaur (16) where longitudinal and transversal dimensions of the braincase are slightly smaller and height diameters (17, 48, 52) are bigger.

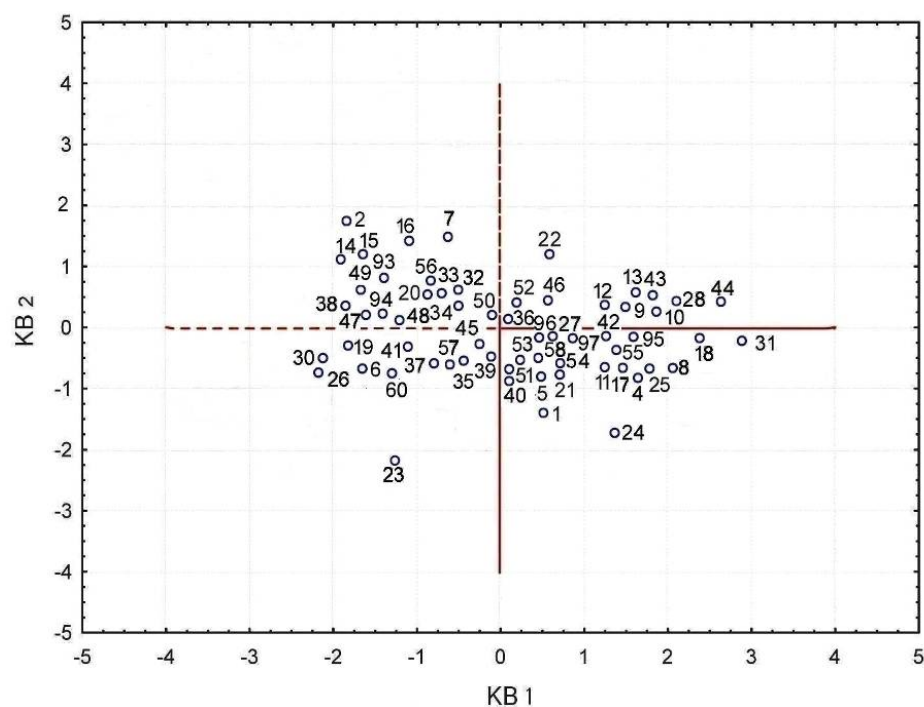


Fig. 20. Place of male craniological series in the space of the first and second canonical vectors.
Numbers of series according to Table 1.

To summarize the materials studied in our article, it should be stressed that the population of medieval Armenia was not homogeneous. Some combinations of craniological features of South-European race are extant. According to the craniological data on our disposal today, among the late medieval population of Hovhannavank are present specific complexes of features not characteristic for the Armenian population of later periods. This complex of features stands close to the Caucasioni type. Closest

analogues to that type were found among the population of Georgia, Azerbaijan (Mingechaur) and Iran (Turang Tepe).

Some comments should be in place regarding the origins of the Caucasioni type. This type was named Caucasioni after the Georgian word for the Caucasus in 1953.³⁷ Based upon specific craniological features of Caucasioni type (extremely wide facial skeleton and some flatness on its upper part, clearly expressed brachycrany), G.F. Debets³⁸ had suggested that they might have genetic connections with the population of the Bronze age Eurasia. Brachycrany of the Caucasioni groups he was inclined to regard as a local and late phenomenon. Eastern European analogues proposed by G.F. Debets³⁹ were adopted by some scholars and treated as an argument for the possible migration of the ancestors of Caucasioni population from the north. Could be referred also the study of N.N. Miklashevskaya⁴⁰ who adds the above mentioned argumentation materials from Dagestan regarding the population of that region during the Sarmatian and Khazar-Alan periods. The ideas of G.F. Debets⁴¹ were further developed by A.V. Shevchenko⁴². Studying the craniological groups of North-Caucasian and Yamnaya cultures which, according to him,⁴³ belong to the “extensive and poorly differentiated anthropological formation embracing the steppes of Eastern Europe during Neolithics and Early Bronze age” and comparing them with the closely related skulls of modern series of Caucasioni types, he shares the suggestion of G.F. Debets regarding the steppe origins of Caucasioni race. V.P. Alekseev⁴⁴ who shares the hypothesis of isolation as the main form-building factor, categorically opposed the idea of the possible northern elements in the formation of Caucasioni people.⁴⁵ He thought that⁴⁶ the isolation had preserved morphological peculiarities of the ancient population which had settled in the highlands of the Caucasus still in Palaeolithics. A.V. Shevchenko⁴⁷ disagrees with V.P. Alekseev⁴⁸ in that “brachycrany of the modern representatives of Caucasioni type is a later formation” and showed that the steppes of the North-western Caspian region and Kalmykia at the end of the III – early II millenniums BC were compact zones of brachycrany. Meanwhile not only the steppes of the North-western Caspian region and Kalmykia were brachycranial zone but during the mentioned period brachycranial variants were fixed in the palaeoanthropological

³⁷ Natishvili, Abdushelishvili 1955: 62-68.

³⁸ Debets 1956: 207-237.

³⁹ Debets 1956: 214.

⁴⁰ Miklashevskaya 1959: 89-110.

⁴¹ Debets 1956: 214.

⁴² Shevchenko 1986: 121-215.

⁴³ Shevchenko 1986: 128.

⁴⁴ Alekseev 1974: 134-138.

⁴⁵ Miklashevskaya 1959: 89-110.

⁴⁶ Alekseev 1974: 134-138.

⁴⁷ Shevchenko 1986: 198-202.

⁴⁸ Alekseev 1974: 100.

materials of the Near East and Armenian Highland.⁴⁹ The idea regarding the formation of Caucasioni type as a result of “conservation” shares also E.A. Javakhishvili.⁵⁰ Autochthonous character of Caucasioni type finds further argumentation in the studies of M.G.Abdushelishvili⁵¹ and A.G.Gajiev.⁵² By M.G.Abdushelishvili the process of brachycephalization and the increase in the skull diameter started during the Bronze Age and it brought to the gradual restructuring of the narrow-faced gracile variants to the modern Caucasioni type. Intense development of that process was fixed during the Middle Ages. To that same opinion came also A.G.Gajiev who had studied palaeoanthropology of Dagestan.

The results of the studies mentioned above tip “the scales” in favor of the concept of the local development of Caucasioni type. What says archaeological data regarding the origins of Caucasioni type? Doubtless, they speak in favor of the mentioned concept. According to A.G.Kozintsev,⁵³ bearers of that type are descendants of the ancient aborigines, population of mountainous regions – tribes who made the coarse ware. In the period before the III millennium BC these peoples, probably, occupy at least all Northern Caucasus. Newcomers from the Southern Caucasus settled down in the western and eastern parts of the Proto-Caucasioni area, made a “pincer movement”. These “pincers” were tightened until the period when the descendants of local population were driven to the mountainous regions (probably, unapproachable for the newcomers) where they were consolidated and form Caucasioni type with its compact area.

About the presence of Caucasioni individuals in Hovhannavank is told by the late medieval Armenian historiographer Zakaria Kanakertsi.⁵⁴ “....When St George was martyred in Cappadocia, his body was kept ... in Hovhannavank... At that time a malicious scab disease hit on the son of the Georgian king, he did not find healing. Then the king was told: “There exists ... a monastery which is called Hovhannavank and there is kept the body of St George and there go all lepers and handicapped people and find healing by St George. Send your son there and he will be cured”.... And so he [the king] decided to send [people] in order to bring bones of St George.... Then the king assembled many nobly children and sent them as hostages they were twelve people who arrived at the gates of Hovhannavank. They (monks) received children and from the relics of the saint they took part of the teeth and blood and the body they prepared for shipment. And so he (St George) remained in the Georgian country, and the sons of the Georgians remained in the Armenian country until now”.

⁴⁹ Khudaverdyan, Gasparian, Pinhasi, Kanayan, Hovhannesyan 2017: 85–86.

⁵⁰ Javakhishvili 1966: 106-107.

⁵¹ Abdushelishvili 1964; 1972: 119-129.

⁵² Gajiev 1975.

⁵³ Kozintsev 1974: 198-214.

⁵⁴ Kanakertsi 1969: 269-271.

Historiography tells⁵⁵ that “The children of Georgians remained in Hovhannavank ... one had died in Hovhannavank. One by the name of Tein remained in Hovhannavank and after him [his descendants] are called Teinenq; the other by the name Azipe went to Yeghvard and now [they] are called Azipenq; the next by the name Mutsa went to Kanaker and they are called Motsakenq; the next one by the name Khacho went to Mogni and [they] are called Khachikenq; one [of them] by the name Stepanos went to Byurakan and gave birth to a son by the name Babajan and they are called Babajanenq; the next by the name Shalove went to Ghazaravan and gave birth to a son by the name Baba and [they] are called Babenq; and someone by the name Gapo took as a wife his sister by the name Aguta, went to Kanaker and they are called Gaponq”.

BIBLIOGRAPHY

Abdushelishvili M.G. 1964. Anthropology of the ancient and modern population of Georgia, Tbilisi (in Russian).

Abdushelishvili M.G. 1972. Materials of the joint Soviet-Indian anthropological studies under the light of common problems of the genesis of Indo-Mediterranean race, Soviet Ethnography 6, 119-129 (in Russian).

Alekseev V.P. 1974. Origins of the Caucasian peoples Moscow (in Russian).

Alekseev V.P., Debets G.F. 1964. Craniometry (the methodology of anthropological studies), Moscow (in Russian).

Alishan G. 1890. Azdarar, Venice (in Arm.).

Aufderheide A.C., Rodríguez-Martín C. 1998. The Cambridge encyclopaedia of human palaeopathology, Cambridge.

Buikstra J.E., Ubelaker D.H. 1994. Standards of data collection from human skeletal remains, Fayetteville (Arkansas Archaeological Survey Research Series).

Davrizheci A. 1891. Book of History, Vagharshapat (in Arm.).

Debets G.F. 1956. Anthropological studies in Dagestan, Studies of the Institute of Ethnography, vol. 33, Moscow, 207–237 (in Russian).

Dyachenko V.I. 1988. Fostering of children among Yakuts. Traditional fostering children among the peoples of Siberia, vol. 8, Leningrad, 46-49 (in Russian).

Gajiev A.G. 1965. Origins of the peoples of Dagestan (according to anthropological data), Makhachkala (in Russian).

Ghafadaryan K. 1948. Hovhannavank and its inscriptions, Yerevan (in Arm.).

Goodman A.H., Martin D.L., Armelagos G.J., Qark G. 1984. Indications of stress from bones and teeth, Paleopathology at the origins of agriculture, New York, 13-49.

Goodman A.H., Armelagos G.J. 1989. Infant and Childhood Morbidity and Mortality Risks in Archaeological Populations, World Archaeology 21 (2), 225–243.

Herodotus 1986. History (transl. by S.Krkyasharyan, Yerevan (in Arm.).

Hershkovitz I., Greenwald C.M., Latimer B., Jellema L.M., Wish-Baratz S., Eshed V., Dutour O., Rothschild B.M. 2002. *Serpens endocrania symmetrica* (SES): a new

⁵⁵ Kanakertsi 1969: 273.

term and possible clue for identifying intrathoracic disease in skeletal populations, *American journal of Physical Anthropology* 118, 201–216.

Hillson S. 1996. *Dental anthropology*, Cambridge.

Hovsepyan G. 1944. *Materials and studies on the history of Armenian art and culture*, vol.III, New York (in Arm.).

Javakhishvili E.N. 1966. The Sioni craniological serie, in Abdushelishvili M.G., *On the craniology of the ancient and modern population of the Caucasus*, Tbilisi, 89–133 (in Russian).

Kanakertsi Z. 1870. *Chronics*, Vagharshapat, vol. III (in Arm.).

Kanakertsi Z. 1969. *Chronics* (transl. from the Armenian and commentaries by M.O. Darbinyan-Mamikonyan, Moscow (in Russian).

Khudaverdyan A.Yu. 2005. *Atlas of palaeopathological finds on the territory of Armenia*, Yerevan (in Russian).

Khudaverdyan A. Yu. 2011a. Artificial modification of skulls and teeth from ancient burials in Armenia /A. Khudaverdyan/, *Anthropos*, volume 106 (2), 602–609.

Khudaverdyan A.Yu. 2011b. Trepanation and artificial cranial deformations in ancient Armenia /A. Yu. Khudaverdyan/, *Anthropological Review*, volume 74/1, 39–55.

Khudaverdyan A.Yu. 2016. Bioarchaeological methods to the study of the traces of artificial influence on the skull (on the example of the Bronze and Early Iron age populations on the territory of Armenia), *Bulletin of archaeology, anthropology and ethnography* 1 (32), 103-114 (in Russian).

Khudaverdyan A.Yu., Zhamkochyan A.S., Hakobyan N.G. 2016. The population of Hovhannavank in the medieval period, *Biological Journal of Armenia* 4, vol. LXIX, 13-21 (in Russian).

Khudaverdyan A.Yu., Gasparyan B.Z., Pinhasi R., Kanayan A.S., Hovhanesyan N.A. 2017. Complex study of the anthropological materials of Late Eneolithics from the cave of Areni 1, *Bulletin of Archaeology, Anthropology and Ethnography*, Tyumen, 2017, N 2 (37), 72-93 (in Russian).

Khudaverdyan A.Yu., Zhamkochyan A.S., Hakobyan N.G., Babayan F.S., Yengibaryan A.A., Khachatryan A.A., Yeganyan L.G. 2018. Anthropological peculiarities of the population of the Armenian Highland and ethnogenetic situation in the Southern Caucasus in the Middle ages, *Bulletin of archaeology, anthropology and ethnography*, Tyumen, N 1 (40), 60-88 (in Russian).

Kostanyants K. 1913. *Lapidary annals*, Saint-Petersburg (in Russian).

Kozintsev A.G. 1974. The Problem of origins of the anthropological types of the Northern Caucasus under the light of archaeology, *Anthropology and Genogeography*, Moscow, 198– 214 (in Russian).

Larsen C.S. 1997. *Bioarchaeology: Interpreting Behavior from the Human Skeleton*, Cambridge.

Lewis M.E. 2004. Endocranial lesions in non-adult skeletons: understanding their aetiology, *International Journal of Osteoarchaeology* 14, 82–97.

Manucharyan A.G. 2019. *Epigraphic-historiographic studies of the Armenian church*, Yerevan (in Arm.).

Miklashevskaya N.N. 1959. Some data on the palaeoanthropology of Dagestan, Materials on the archaeology of Dagestan, vol.I, Makhachkala, 89–110 (in Russian).

Movsesyan A.A. Mamonova N.N., Richkov Yu.G. 1975. The program and methodology of the study of the skull anomaly, Problems of Anthropology, vol. 51, 127-150 (in Russian).

Natishvili A.N., Abdushelishvili M.G. 1955. Preliminary data on the anthropological studies of the Georgian people, Brief Communications of the Institute of Ethnography, vol. XXII, Moscow, 60–71 (in Russian).

New dictionary of the Armenian language (Haykazyan) 1981. Vol. II, Yerevan (in Arm.).

Nussinovitch M., Yoeli R., Elishkevitz K., Varsano I. 2004. Acute mastoiditis in children: Epidemiologic, clinical, microbiologic, and therapeutic aspects over past years, Clinical Pediatrics (Phila), № 43, 261–267.

Orbeli I.A. 1915. The inscription of the Sanahin bridge, The Christian East, vol. IV, p. II, Petrograd (in Russian).

Ortner D.J. 2003. Identification of pathological conditions in human skeletal remains. 2nd edition, San Diego and London.

Ortner D. J., Putschar W.G.J. 1981. Identification of Pathological Conditions in Human Skeletal Remains, Washington.

Popov A.N., Chikasheva T.A., Shpakova E.G. 1997. The Boysman archaeological culture of the Southern Primorye (on the materials of the multi-layered monument of Boysman-2), Novosibirsk (in Russian).

Shahaziz Ye. 1987. The History of Ashtarak, Yerevan (in Arm.).

Shevchenko A.V. 1986. Anthropology of the South-Russian steppes in the Bronze age, in Anthropology of the modern and ancient population of the European part of the USSR, Leningrad, 121–215 (in Russian).

Toramanyan T. 1948. Materials on the history of Armenian architecture, vol.II, Yerevan (in Arm.).

Trofimova T.A. 1956. Anthropological composition of the city of Bolgar in the X–XV centuries, Studies of the Institute of Ethnology. Anthropological collection 1, vol. XXXIII, Moscow, 73–115 (in Russian).

Ubelaker D.H. 1989. Human Skeletal Remains: Excavation, Analysis, Interpretation, 2nd edition, Washington.

Zakaryan L.D. 1973. On one relief of Hovhannavank, Journal of History and Philology 1, 292-296 (in Arm.).

Zhirov E.V. 1940. On the artificial deformation of the skull, Brief communications of the Institute of the history of material culture, Moscow, vol.8, 81-88 (in Russian).

Zubov A.A. 1968a. Odontology (the methodology of anthropological studies), Moscow (in Russian).

Zubov A.A. 1968b. Some odontological data concerning the problem of the evolution of man and its races, in Problems of the evolution of man and its races, Moscow, 5–122 (in Russian).

Table 1**Individual, average measurements and indices of late medieval skulls from Hovhannavank**

№ by Martin and others	Feature	I ♀	II ♂	III ♀	IV ♂	V ♀	VI ♂	♂	♀
1	Longitudinal diameter	170	168	165	169	–	–	168.5	167.5
8	Transversal diameter	147	133	140	140	145	142	138.4	144
8:1	Skull indicator	87.36	79.17	84.85	82.85	–	–	81.1	86.2
17	Height diameter from ba	133	134	142	135	125?	–	134.5	133.4
17:1	Height-longitudinal indicator	78.24	79.77	86,07	79.89	–	–	79.9	82.2
17:8	Height-transversal indicator	89.57	100.76	101,43	96.43	86.21	–	98.6	92.4
20	Height diameter from po	117	119.8	117.9	115	–	–	117.4	117.5
20:1	Height-longitudinal indicator	68.83	71.31	71.46	68.05	–	–	69.7	70.2
20:8	Height-transversal indicator	79.592	90.08	84.22	82.15	–	–	86.2	81.91
5	Height of the skull base	98.5	98	101.5	97	–	–	97.5	100
9	The least width of the forehead	91.5	97	103	89.2	–	–	93.1	97.3
9:8	Frontal-transversal indicator	61.62	72.94	73.58	63.72	–	–	68.33	67.6
10	Maximum width of the forehead	122	119	127	119	–	–	119	124.5
11	Width of the skull base	122	123	122	127	129	117	122.4	124.4
11:8	Auricular-transversal indicator	82.99	92.49	87.15	90.72	88.9 7	82.39	88.6	86.4

12	Width of the nape	115	107.5?	109	113	111	106	108.9	111.7
29	Frontal chord	111.5	111.5	107	111.5	–	–	111.5	109.3
30	Parietal chord	104	101	108	102	103	111	104.7	105
31	Occipital chord	96?	100.5	92.5	102.8	94.2	93	98.8	94.3
40	Length of the base of the face	83.5	97.8	88	101	–	–	99.4	85.8
40:5	Indicator of the relief of the face	84.78	99.796	86.69	104.13	–	–	101.97	85.8
45	Skull diameter	127.5	136	126.5	133	–	–	134.5	127
48	Upper height of the face	62.8	76	71	76.8	–	–	76.4	66.9
45:8	Transversal faciocerebral indicator	86.74	102.26	90.36	95	–	–	98.7	88.6
9:45	Parietal-zygomatic indicator	71.77	71.33	81.43	67.07	–	–	69.2	76.6
48:17	Vertical faciocerebral indicator	47.22	81.35	50	56.89			69.2	48.7
48:45	Upper facial indicator	49.26	55.89	56.13	57.75	–	–	56.83	52.7
46	Medium width of the face	90.5	101.5	89.5	92	–	–	96.8 (2)	90 (2)
60	Length of the alveolar arc	47?	54	48	55?	–	–	54.5	47.5
61	Width of the alveolar arc	52.8	61.8	60.5	60.5	–	–	61.2	56.7
62	Length of the palate	37.8?	43.7	38	49	–	–	46.4	37.9
63	Width of the palate	31	35	31	34.5?	–	–	34.8	31
63:62	Palatial indicator	82.02	80.092	81.58	70.41	–	–	75.3	81.8
55	Height of the nose	54	59	52	55	–	–	57	53
54	Width of the nose	26?	29	22	24	–	–	26.5	24
54:55	Nasal indicator	48.15	49.16	42.31	43.64	–	–	46.4	45.3
51	Width of the orbit from mf	40.8	44	43	41?	–	–	42.5	41.9
51a	Width of the orbit from d	38	40	37.8	38	–	–	39	37.9
52	Height of the	35.5	35.5	36	38	–	–	36.8	35.8

	orbit								
52:51	Orbital indicator (mf)	87.01	80.69	83.73	92.69	–	–	86.7	85.4
52:51	Orbital indicator (d)	93.43	88.75	95.24	100	–	–	94.4	94.4
MC	Maxillofrontal width	16	21.8	21	18	–	–	19.9	18.5
MS	Maxillofrontal height	9	11.5	10	10	–	–	10.8	9.5
MS:MC	Maxillofrontal indicator	56.25	52.76	47.62	55.56	–	–	54.2	51.94
DC	Dacrial width	18.5	27	27	22	–	–	24.5	22.8
DS	Dacrial height	13	17.5	16	11.5	–	–	14.5	14.5
DS:DC	Dacrial indicator	70.28	64.82	59.26	52.28	–	–	58.6	64.8
SC	Symotic width	9	14.5	10.2	8.2	–	–	11.4	9.6
SS	Symotic height	4.5	8	5	3.8	–	–	5.9	4.8
SS:SC	Symotic indicator	50	55.18	49.02	46.35	–	–	50.8	49.6
32n	Angle of the face profile from nasion	82	81	86	80	–	–	80.5	84
32gl	Angle of the forehead profile from glabella	80	75	82	71	–	–	73	81
72	Overall facial angle	97?	88	88	78	–	–	83	87.5
73	Medium facial angle	92	87	84	79	–	–	83	88
74	Angle of the alveolar part	99?	99	98	77	–	–	88	98.5
75(1)	Angle of the nose protrusion	31	34	32	32	–	–	33	31.5
77	Nasomalar angle	139	135	131	145	–	–	140	135
<zm	Zygomaxillary angle	125	126	126	125	–	–	125.5	125.5
68 (1)	The length of the lower jaw from the condyles	99	93.8	103	108	–	–	100.9	101
79	Mandibular branch angle	32.5	39	42	30.5	–	–	34.8	37.3
68	Lower jaw length from corners	73	73.8	73.2	80	–	–	76.9	73.1
70	Height of the lower jaw branch	60.5	61	52	68	–	–	64.5	56.3
71a	The smallest	27	30	29.2	32	–	–	31	28.1

	width of the lower jaw branch								
65	Condylar width	114	116	114	120	–	–	118	114
66	Angular width	96	103	107	103	–	–	103	101.5
67	Frontal width	43	41.8	43	50	–	–	45.9	43
69	Height of symphysis	27	29.5	32.8	30	–	–	29.8	29.9
69 (1)	Height of the body	21	26.8	23.5	27	–	–	26.9	22.3
69 (2)	Thickness of the body	11	12	13	17	–	–	14.5	12
47	Complete height of the face	125?	118.8	113.5	124.5	–	–	121.7	119.3

Table 2. Dimensions of teeth of individuals from Hovhannavank

	Lower jaw							
	Vestibular-lingual diameter VL _{cor}							
	Individual 1. right left		Individual 2. right left		Individual 3. right left		Individual 4. right left	
I1	–	–	–	–	–	–	–	–
I2	–	–	–	–	–	–	–	–
C	–	–	–	–	7.6	7.9	8.1	–
P1	–	–	–	7.7	–	7.6	7.5	7.5
P2	–	–	–	–	–	–	7.9	7.8
M1	–	–	–	–	10.2	10	10.8	9.9
M2	–	–	9.4	–	9.9	9.9	10.4	–
M3	8.5	9	9.5	9.4	–	–	–	–
	Mesio-distal diameter MD _{cor}							
I1	–	–	–	–	–	–	–	–
I2	–	–	–	–	–	–	–	–
C	–	–	–	–	6.8	6.8	6.8	–
P1	–	–	–	6.2	–	7.3	6.9	6.5
P2	–	–	–	–	–	–	7.1	6.8
M1	–	–	–	–	10.8	10.8	11.2	10.1?
M2	–	–	10.7	–	11	11	10.3	–
M3	7.9?	10.1	10.8	10.5	–	–	–	–
	Height of the crown H _{cor}							
M1	–	–	–	–	7.1	7.6	3.7	–
M2	–	–	4.5	–	7.1	7.6	3	5.2
M3	3.8	5.1	3.3	3.5	–	–	–	–
	Mesio-distal diameter of the cervix MD _{col}							
M1	–	–	–	–	8.3	8.5	8.7	–

M2	–	–	7.8	–	9.8	9.3	8.6	8.9
M3	–	–	8.9	8.9	–	–	–	–
	Area of the cervix $MD \times VL$							
M1	–	–	–	–	110.16	108	120.96	99.99
M2	–	–	100.58	–	108.9	108.9	107.12	–
M3	67.15	90.9	102.6	98.7	–	–	–	–
	Index of the cervix $I_{cor} (VL / MD) \times 100$							
M1	–	–	–	–	94.45	92.6	96.43	98.02
M2	–	–	87.86	–	90	96.43	100.98	–
M3	107.6	89.11	87.97	89.53	–	–	–	–
	Module of the cervix m_{cor} $MD + VL / 2$							
M1	–	–	–	–	10.5	10.4	11	10
M2	–	–	10.05	–	10.45	10.45	10.35	–
M3	8.2	9.55	10.15	9.95	–	–	–	–
	Upper jaw Vestibular-lingual diameter VL_{cor}							
	right left		right left		right left		right left	
I1	–	–	–	–	–	–	–	–
I2	–	–	–	–	–	–	6.5	6.3
C	–	–	–	–	–	–	8.2	8.6
P1	–	–	–	–	–	–	8.9	8.8
P2	–	–	–	–	–	–	8.8	–
M1	–	–	–	–	11	11.5	–	–
M2	–	–	10.2	10.2	12.2	12	–	–
M3	10	–	–	–	–	–	–	–
	Mesio-distal diameter MD_{cor}							
I1	–	–	–	–	–	–	–	–
I2	–	–	–	–	–	–	6.7	6.5
C	–	–	–	–	–	–	6.7	6.2
P1	–	–	–	–	–	–	6.9	6.3
P2	–	–	–	–	–	–	5.6	–
M1	–	–	–	–	10.6	10.7	–	–
M2	–	–	8.8	8.7?	9.9	9.8	–	–
M3	7.9	–	–	–	–	–	–	–
	Height of the crown H_{cor}							
M1	–	–	–	–	6	6.9	–	–
M2	–	–	4.5	4.4	7.2	7	–	–
M3	4.8	–	–	–	–	–	–	–
	Mesio-distal diameter of the cervix MD_{col}							
M1	–	–	–	–	6.5	7.5	–	–
M2	–	–	7.4	7.3?	7.8	8.5	–	–
M3	6.2	–	–	–	–	–	–	–

	Area of the cervix $MD \times VL$							
M1	–	–	–	–	116.6	120.05	–	–
M2	–	–	89.76	88.74	120.78	117.6	–	–
M3	79	–	–	–	–	–	–	–
	Index of the cervix $I_{cor} (VL / MD) \times 100$							
M1	–	–	–	–	103.78	107.48	–	–
M2	–	–	115.91	117.25	123.24	122.45	–	–
M3	126.6	–	–	–	–	–	–	–
	Module of the cervix $m_{cor} MD + VL / 2$							
M1	–	–	–	–	10.8	11.1	–	–
M2	–	–	9.5	9.45	11.5	10.9	–	–
M3	8.95	–	–	–	–	–	–	–

Table 3. List of series, involved for the analysis

	Region, site, serie	Date
1	Dvin	V–VI c.
2	Armavir	XII–XIII c.
3	Byurakn (deformed skulls)	XII–XIII c.
4	Hovhannavank	–
5	Garni	Early-feudal period
6	Benyamin	II – III B.
7	Georgia: Samtavro	IV–IXвв. (early-feudal period)
8	Georgia: Rustavi	Late-feudal period
9	Georgia: Dusheti	–
10	Georgia: Khevsuri	–
11	Georgia: Sioni I	VII–X c.
12	Georgia: Sioni II	XII–XIII c.
13	Georgia: Sioni III	XVII–XVIII c.
14	Mingeaur I (catacomb burials /without deformation of the skull/)	I–VII c.
15	Mingeaur II (catacomb burials /slight deformation of the skull/)	–
16	Mingeaur III (catacomb burials /strong deformation of the skull/)	–
17	Mingeaur IV (burials of Christian type)	VII–IX c.
18	Samukh region of Azerbaijan (burials of Muslim type)	XIV–XVII c.
19	Mesopotamia: Nippur	IX–X c.
20	Mesopotamia: Tell Gubba	Islamic period
21	Mesopotamia: Tell Songar	Islamic period
22	Mesopotamia: Assur	Islamic period
23	Turkey: Boghazköi	V–XI c.

24	Iran: Shah Tepe	VIII–X c. (Islamic period)
25	Iran: Turang Tepe	X c.
26	Israel: Bedouin	XVII–XVIII c.
27	Dagestan: Upper Chir-Yurt	V–VII c.
28	Dagestan: Gotsatl	VIII–X c.
29	Dagestan: Degva	–
30	Dagestan: Uzuntala	IX–XI c.
31	Dagestan: Miatli	XII–XIII c.
32	Krasnodar district: Gamovskoe and nearby gorges	V–VII c.
33	Krasnodar district: Zhukova	XIII–XIV c.
34	Krasnodar district: Ilichevsk hillfort	XIV–XVI c.
35	Krasnodar district: temple near the village Veseloe, tomb	IX–XI c..
36	Krasnodar district: temple near the village Veseloe, necropolis of the temple	–
37	Krasnodar district: temple near the Veseloe village, nave	–
38	Krasnodar district: temple near the Veseloe village, narthex	–
39	Karachaevo-Circassia: early group	III–V c.
40	Karachaevo-Circassia: later group	VIII–XII c.
41	Karachaevo-Circassia: Lower Arkhiz	–
42	Kabardino-Balkaria: Chegem	XIV–XV c.
43	Kabardino-Balkaria: Lower Julat	–
44	Northern Ossetia: Mozdok	XII–XIV c.
45	Northern Ossetia: Zmeiskaya	X–XII c.
46	Northern Ossetia: Upper Julat	XIV–XVII c.
47	Northern Ossetia: Mamison don (in total)	VIII–X c.
48	Northern Ossetia: Mound-1	–
49	Northern Ossetia: OCHM	–
50	Northern Ossetia: Dzavgis-15	XIV–XVI c.
51	Northern Ossetia: Dzavgis-18	–
52	Northern Ossetia: Dzavgis -21	–
53	Northern Ossetia: Dzavgis -3	–
54	Northern Ossetia: Upper Koban	XIV–XVI c.
55	Ossetia: Kharkh	X–XIII c.
56	Checheno-Ingushetia: Duba-Yurt	IX–X c.
57	Checheno-Ingushetia: Keli-1	XIV–XVI c.
58	Checheno-Ingushetia: Keli-2	–
59	Stavropol region: Majari	XIV–XV c.
60	North-western Caucasus: Moshshevaya Balka	VI–VIII c.
61	Lower Volga-Lower Don region (in total)	II–IV c.
62	–	V–VII c.
63	–	VII–IX (X) c.
64	Astrakhan region: Bugor Vakurovskij	XIV c.
65	Astrakhan region: Mayachnij II	–

66	Astrakhan region: Samosdelka	XVI c.
67	Volga Bulgaria: City of Bilyar	X–XIII c.
68	Volga Bulgaria: City of Bulgar “Ladies hill”: summarily	X–XV c.
69	Volga Bulgaria: City of Bulgar “Ryadovoy”	–
70	Volga Bulgaria: City of Bulgar “Chetyrekhugol'nik”	X–XIII c.
71	Volga Bulgaria: City of Bulgar “Minaret”	XIII–XV c.
72	Volga Bulgaria: City of Bulgar - “Cultural layer”	–
73	Volga Bulgaria: City of Bulgar - “Greek palace”	XIV c.
74	Middle Volga: The cemetery of khan	XIV–XV c.
75	Middle Volga: Quadrangle 1	X–XIII c.
76	Middle Volga: Quadrangle 2	XIII–XV c.
77	Middle Volga: Quadrangle 3	X–XII c.
78	Middle Volga: 1 Starokuybishevskij	Before Golden Horde
79	Middle Volga: 1 Starokuybishevskij	Golden Horde period
80	Middle Volga: Izmerskij	XI–XIII c.
81	Middle Volga: Taktalachukskij	XIII–XIV c.
82	Middle Volga: Azmetevskij	–
83	Middle Volga: Barbashina Polyana	–
84	Middle Volga: The city of Bulgar (P 45)	–
85	Middle Volga: Murom townlet	X–XIII c.
86	Middle Volga: Mausoleums of the city of Bulgar	–
87	Middle Volga: Memorable sign	–
88	Middle Volga: the region of former airfield	–
89	Middle Volga: mausoleum of stone (CLXXIV)	–
90	Middle Volga: north of the townlet of Bulgar (CXCI)	–
91	Volga-Ural: Bukeevskaya steppe	XIV c.
92	Ukraine: Chigirin	XVI–XVII c.
93	Western Ukraine	Chernyakhov culture
94	Danube-Dniestr region: Bujak	–
95	Moldova: Old Orkhey -1	XIV c.
96	Moldova: Old Orkhey -2	XV c.
97	Moldova: Old Orkhey -3	XVI–XVII c.

Table 4. Elements of first three canonical vectors (CV). Males

№ by Martin and others	Feature	CV I	CV II	CV III
1	Longitudinal diameter	<u>-0,579</u>	-0,121	0,355
8	Transversal diameter	<u>0,819</u>	0,215	-0,245
17	Height diameter	-0,304	0,182	-0,232

9	Minimal width of the forehead	<u>-0,584</u>	0,347	-0,176
45	Zygomatic width	0,306	-0,173	-0,199
48	Upper height of the face	0,016	-0,003	0,200
55	Height of the nose	0,156	-0,064	-0,015
54	Width of the nose	0,052	0,344	0,190
51	Width of the orbit from mf	0,289	0,080	0,170
52	Height of the orbit	-0,208	0,645	-0,043
77	Nasomalar angle	-0,034	0,158	0,294
zm	Zygomaxillary angle	0,119	0,095	0,518
SS:SC	Symotic indicator	0,002	0,291	0,365
75(1)	Angle of the protrusion of the nose	-0,260	0,207	<u>-0,736</u>
Percentage in overall dispersion (%)		29,970	23,369	13,291

Table 5. Elements of first three canonical vectors (CV). Females

№ by Martin and others	Feature	CV I	CV II	CV III
1	Longitudinal diameter	0,034	<u>0,582</u>	0,503
8	Transversal diameter	0,095	<u>-0,799</u>	-0,464
17	Height diameter	0,240	0,151	-0,220
9	Minimal width of the forehead	-0,102	<u>0,551</u>	-0,100
45	Zygomatic width	-0,038	0,029	0,130
48	Upper height of the face	<u>-0,645</u>	-0,056	0,216
55	Height of the nose	<u>0,699</u>	0,017	-0,035
54	Width of the nose	0,167	-0,094	0,115
51	Width of the orbit from mf	-0,016	-0,317	-0,126
52	Height of the orbit	<u>0,705</u>	0,040	-0,116
77	Nasomalar angle	0,160	-0,108	0,330
zm	Zygomaxillary angle	0,179	-0,173	0,399
SS:SC	Symotic indicator	0,065	-0,105	0,444
75(1)	Angle of the protrusion of the nose	0,183	<u>0,561</u>	<u>-0,686</u>
Percentage in overall dispersion (%)		43,854	21,460	9,423

Table 6. Elements of first three canonical vectors (CV). Males

№ by Martin and others	Feature	CV I	CV II	CV III
1	Longitudinal diameter	<u>-0,767</u>	0,147	0,065
8	Transversal diameter	<u>0,803</u>	-0,255	-0,300

17	Height diameter	0,030	0,300	0,231
9	Minimal width of the forehead	-0,289	-0,306	0,164
45	Zygomatic width	0,229	-0,101	<u>0,861</u>
48	Transversal diameter	-0,031	-0,217	<u>0,585</u>
55	Height of the nose	0,062	<u>0,520</u>	-0,293
54	With of the nose	0,100	-0,174	-0,139
51	Width of the orbit from mf	0,361	<u>0,931</u>	-0,475
52	Height of the orbit	-0,008	-0,252	-0,037
Percentage in overall dispersion (%)		46,800	10,854	10,262

Translated from the Russian by Aram Kosyan